

# En face swept-source optical coherence tomography in wet age-related macular degeneration.

The hallmark of wet age-related macular degeneration (AMD) is choroidal neovascularization (CNV) that can be mainly classified following either angiographic or tomographic findings. According to fluorescein angiography (FA), CNV can be classified as occult, minimally classic (classic component <50% of total lesion size) or predominantly classic (classic component >50% of total lesion size). According to optical coherence tomography (OCT), CNV can be classified as type 1 (below the retinal pigment epithelium or RPE), type 2 (above the RPE) and type 3 (intraretinal location as typically seen in retinal angiomatous proliferation or RAP).<sup>1</sup>

Swept-source (SS) OCT allows the study of deeper layers of the eye, such as choroid and sclera, as compared to time domain (TD) OCT or even spectral domain (SD) OCT. This new technology employs a longer wavelength light source, around 1050 nm, compared to the 840 nm wavelength typically used in SD-OCT. Due to the higher imaging speed, more scans can be averaged in a shorter time frame resulting in higher quality scans. The higher speed capturing images and the uniform image quality over depth appears to allow for better resolution in the study of some chorioretinal diseases.

En face SS-OCT mode provides a coronal view of the choroid and retina of the posterior segment at different depth levels. It supplies additional information to conventional cross-sectional imaging, allowing the physician to make rapid diagnosis across the macula, in a non-invasive manner.<sup>2-6</sup>

The SS-OCT device employed by us was DRI-1 Atlantis OCT (Topcon Corporation, Tokyo, Japan) which uses a tunable laser as a light source operated at 100,000 Hz, A-scan repetition rate at 1050 nm of wavelength. The device can perform image averaging of up to 96 B scans at each

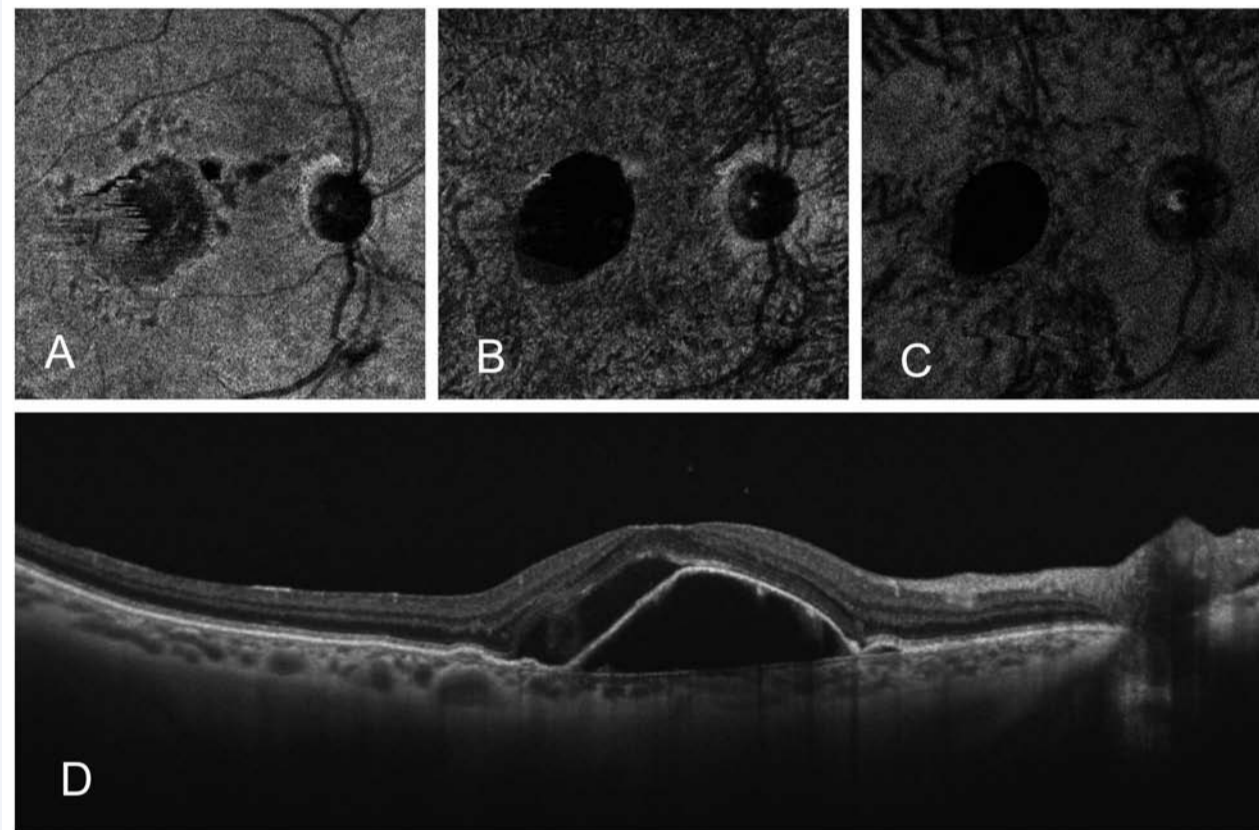


Figure 1. Female, 73 yo. Wet AMD in right eye treatment naïve. VA=20/100. En face SS-OCT at RPE level (A), at Sattler's layer (B) and at Haller's layer (C). SS-OCT showing RPE detachment and subretinal fluid (D).

location. The reference mirror was placed at a deeper position of the retina so that the sensitivity was higher at the choroid. A three dimensional volumetric scan (3D), which produces an OCT image containing 512 x 256 axial scans with a scan length of 12 x 9 mm was employed. This sampling space in object space corresponds to 11.7 µm/pixel. Lateral resolution was set to be 20 µm with 24 mm axial eye length while axial resolution was 8 µm in retina. Lateral and axial resolution is independent. Acquisition time was 1 second. Horizontal and vertical line scans containing 1,024 axial scans with 12 mm length were also performed.

En face, or C-scan, images were obtained with a prototype software provide by Topcon (Topcon Corporation, Tokyo, Japan) which generates

the images after an automatic flattening at RPE level, using the three dimensional volumetric scan of 12 x 9 mm. This segmentation allows a better quality of the images due to the correction of the concavity of the eye, correction of tilted tomography, correction of anatomic distortions due to retinal edema and/or subretinal fluid. The software also allows an image averaging up to 25 times to increase the image quality.

En face images were obtained at different planes<sup>7</sup>: 1) most superficially at the RPE level, 2) just below the RPE to image the choriocapillaris, 3) at Sattler's layer or medium-diameter vessels layer level, 4) at Haller's layer or large-diameter vessels layer, 5) at the choroid-sclera junction.

We compared the CNV in en face SS-OCT with other imaging modalities,

such as FA and indocyanine green angiography (ICGA). The lesions in the en face SS-OCT and FA images were measured with the calliper provided by the devices.

We studied 38 eyes with the recent diagnosis of wet AMD, 22 eyes being classified as type 1 CNV, 5 eyes as type 2, 7 eyes as mixed type 1 and 2, and 4 eyes as type 3 or RAP lesions (Figures 1 and 2).<sup>8</sup>

En face images at RPE level revealed changes in all eyes with the CNV appearing hyporeflective in 76.3% of the cases. At the choriocapillaris level, en face images showed pathological changes in all cases as well, being hyper-reflective in 52.6% of the eyes. Likewise, at Sattler's layer, 52.6% of the eyes showed hyper-reflective lesions. At Haller's layer, 50% of the eyes showed hyper-reflective

lesions. No differences were found between the CNV area and the horizontal and vertical diameters measured in the en face image and FA.

Interestingly, in 52.6% of the studied eyes the medium and large diameter choroidal vessels displayed a radial disposition around the CNV.

In four eyes which presented with small, early lesions, both the RPE and choriocapillaris layers were affected in en face images but no alterations could be detected in the deeper vascular choroidal layers.

However, it's important to take into account that en face imaging can underestimate lesions with significant axial anatomical distortion of the retinal layers, such as RPE detachments, large subretinal fibrosis or large amount of subretinal or intraretinal fluid due to the fact that the images are reconstructed after flattening at the RPE level.

In conclusion, en face SS-OCT is a rapid, non-invasive, high-resolution technology that offers a promising alternative to angiography to study neovascular AMD. There seems to be a correlation between FA findings and en face SS-OCT images in these patients.

Hyporeflective changes are predominant at RPE level while hyper-reflective changes are predominant at the level of choriocapillaris, Sattler's layer and Haller's layers. These preliminary results should be corroborated in larger clinical studies.

Luis Arias, MD, PhD. Head of Retina Department. Department of Ophthalmology. Bellvitge University Hospital. Associate Professor of Ophthalmology. University of Barcelona.  
Ignacio Flores-Moreno, MD, PhD. Department of Ophthalmology. San Carlos University Hospital. Madrid.

supported by: Topcon Europe Medical B.V.  
www.topcon-medical.eu

## REFERENCES

- Freund KB, Zweifel SA, Engelbert M. Do we need a new classification for choroidal neovascularization in age-related macular degeneration? *Retina* 2010;30(9):1333-49.
- Alasil T, Ferrara D, Adhi M, et al. En face imaging of the choroid in polypoidal choroidal vasculopathy using swept-source optical coherence tomography. *Am J Ophthalmol* 2015;159(4):634-43.
- Itakura H, Kishi S, Li D, Akiyama H. En face imaging of posterior precortical vitreous pockets using swept-source optical coherence tomography. *Invest Ophthalmol Vis Sci* 2015;56(5):2898-900.
- Imai A, Toriyama Y, Ieasto Y, et al. En face swept-source optical coherence tomography detecting thinning of inner retinal layers as an indicator of capillary nonperfusion. *Eur J Ophthalmol* 2015;25(2):153-8.
- Sayanagi K, Gomi F, Akiba M, et al. En face high-penetration optical coherence tomography imaging in polypoidal choroidal vasculopathy. *Br J Ophthalmol* 2015;99(1):29-35.
- Ferrara D, Mohler KJ, Waheed N, et al. En face enhanced-depth swept-source optical coherence tomography features of chronic central serous chorioretinopathy. *Ophthalmology* 2014;121(3):719-26.
- Staurenghi G, Sadda S, Chakravarthy U, Spaide RF. Proposed lexicon for anatomic landmarks in normal posterior segment spectral-domain optical coherence tomography: The IN-OCT consensus. *Ophthalmology* 2014;121(8):1572-8.
- Flores-Moreno I, Arias-Barquet L, Rubio-Caso MJ, et al. En face swept-source optical coherence tomography in neovascular age-related macular degeneration. *Br J Ophthalmol* 2015 Feb 26 [Epub ahead of print]. Doi: 10.1136/bjophthalmol-2014-306422.

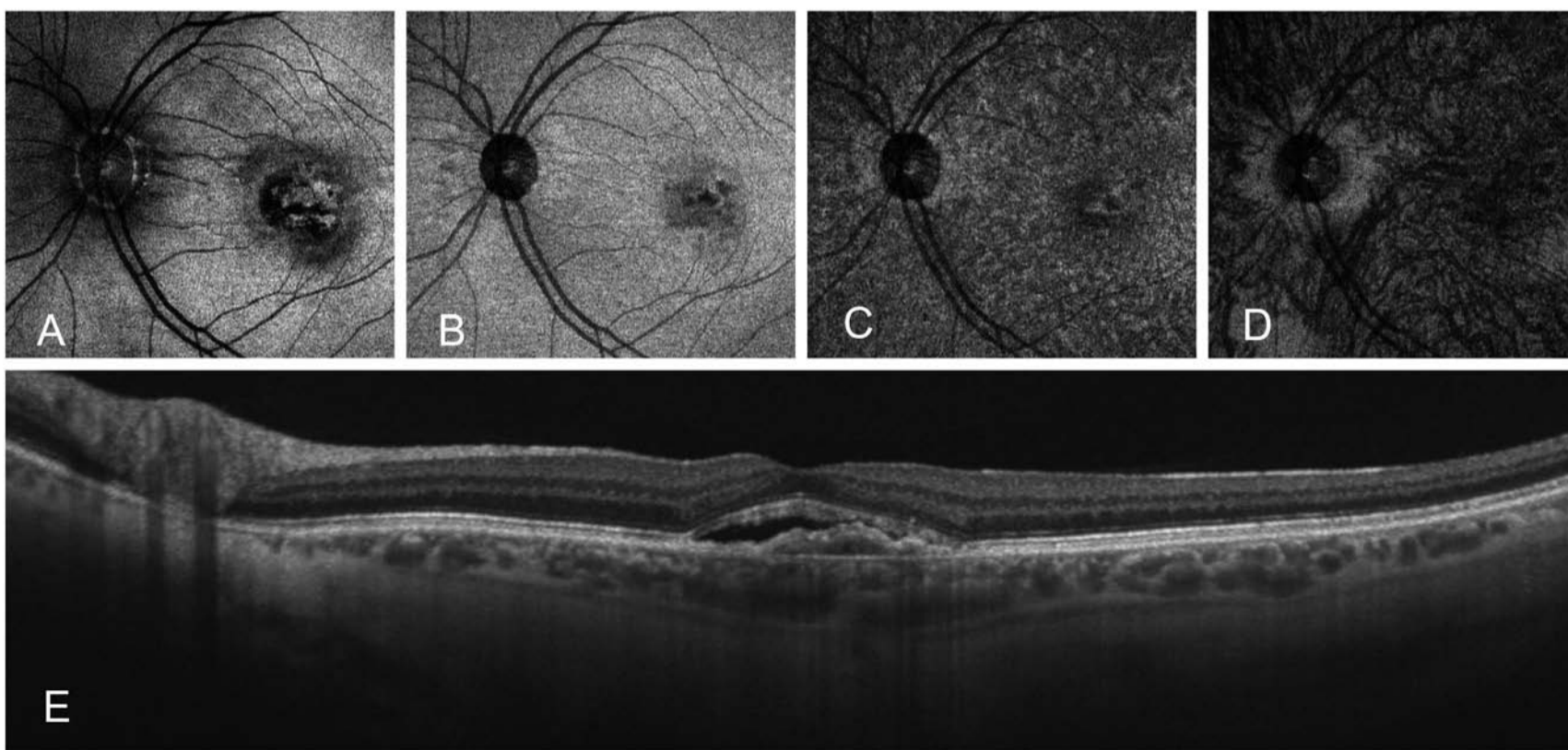


Figure 2. Male, 60 yo. Wet AMD in left eye treated with five intravitreal injections of ranibizumab so far. VA=20/40. En face SS-OCT just above RPE level (A), at RPE level (B), at choriocapillaris level (C) and at Sattler's layer (D). SS-OCT showing RPE detachment and subretinal fluid (E).